

## FREQUENCY OF CRANIAL VAULT FRACTURES IN PATIENTS WITH HEAD INJURY.

Zeeshan Jamal<sup>1</sup>, Pardeep Kumar<sup>2</sup>, Nadia Aslam<sup>3</sup>, Ejaz Ahmed Awan<sup>4</sup>, Abdul Samad<sup>5</sup>

### ABSTRACT:

**INTRODUCTION:** The rate of frontal bone injury has been accounted for to be as high of all instances of skull fractures in patients with a head injury. The frontal bone is the fundamental bone in the brow territory. **OBJECTIVE:** The purpose is to investigate the frequency of cases and cause of head injury in patients. A one year (2019) retrospective study of head-injured patients. **PATIENTS AND METHODS:** Cause of injury, and radiological findings were analyzed of 521 patients in which the majority of patients are from rural dwellers 291 (55/9%) than urban dwellers 230 (44.1%) correspondingly. **RESULT:** The total number of cases of head injury in Radiology and Forensic Medicine Department Peoples Medical College Hospital Nawabshah in the year 2019 was 521 cases, out of those cases violent head injury was the common cause of head injury in patients 209 (38.4%). The 521 patients in which most injured cranial bone is Frontal bone 217 (39.9%). **CONCLUSION:** The study highlight that most of the patients are from rural and among them, the most common cause of head injury is violent assault and mostly injured cranial bone injury is frontal bone

**KEY WORDS:** Cranial Vault Injury, Head Injury, Violent Assault.

1. Assistant Professor, Department of Radiology, Peoples University of Medical & Health Sciences for Women, Nawabshah, S.B.A.
2. Associate Professor, Forensic Medicine & Toxicology Peoples University of Medical & Health Sciences for Women, Nawabshah, S.B.A.
3. Lecturer Forensic Medicine & Toxicology, Liaquat University of Medical & Health Sciences, Jamshoro.
4. Associate Professor & Chairman Forensic Medicine & Toxicology Peoples University of Medical & Health Sciences for Women, Nawabshah, S.B.A.
5. Assistant Professor Forensic Medicine & Toxicology Peoples University of Medical & Health Sciences for Women, Nawabshah, S.B.A.

**For correspondance:** Dr. Ejaz Ahmed Awan, Associate Professor & Chairman Forensic Medicine & Toxicology, Peoples University of Medical & Health Sciences for Women, Nawabshah, S.B.A. email: [forensicawan@outlook.com](mailto:forensicawan@outlook.com)

**How to cite this article:** Jamal Z<sup>1</sup>, Kumar P<sup>2</sup>, Aslam N<sup>3</sup>, Awan EA<sup>4</sup>, Samad A<sup>5</sup> **FREQUENCY OF CRANIAL VAULT FRACTURES IN PATIENTS WITH HEAD INJURY.** *JPUMHS*; 2021;11:03, 63-66. <http://doi.org/10.46536/jpumhs/2021/11.03.317>

*Received December 30<sup>th</sup> 2020, Accepted On 25<sup>th</sup> April 2021, Published On 30<sup>th</sup> September 2021.*

### INTRODUCTION

The rate of frontal bone injury has been accounted for to be as high of all instances of skull fractures in patients with a head injury. The frontal bone is the fundamental bone in the brow territory.<sup>1</sup> A high-sway injury to the head can cause a crack of the frontal bone and floor of the sinuses. The crack is generally liable to happen in the brow that is the place the bone is the most slender and most fragile.<sup>2</sup> A physical concern may make the bone be indented (pushed internal). Generous power is needed to crack the frontal bone, so frequently different wounds to the face, and

skull or neurological injury might be available. Related concern may incorporate spillage of the cerebrospinal liquid, eye wounds, and harm to the sinus pipes. The real occurrence of the frontal bone break is more likely than not higher because it has been demonstrated that numerous worldly bone injuries are missed on the x-rays and can be seen on tomography. Frontal bone cracks can be confined to facial wounds or can expand intracranial. The frontal sinus has a foremost and back divider. Breaks to the front plate alone are facial wounds, requiring restorative careful treatment whenever discouraged.

Breaks to the back plate are Calvary wounds and convey a few dangers, including intracranial disease (from the defilement of the cerebrovascular liquid with nostril air and liquid from the frontal sinus), intracranial drain, and direct horrible mind injury if crack parts are extended back. We had performed a retrospective one-year study review analysis of all cases of head injury treated in our Radiological & Forensic Medicine Department Peoples Medical College Hospital, Nawabshah, Shaheed Benazir Abad, Sindh, Pakistan. We aimed to investigate the cause of cranial vault injury and to evaluate cranial vault injury based on gender distribution, radiological findings and results.

## METHODOLOGY

The clinical records of all patients with head injury conceded to the Peoples Medical College Hospital, Nawabshah, Shaheed Benazir Abad, Sindh, Pakistan) in 2019 were contemplated. All recognized outlines were inspected for radiological affirmation of frontal bone crack through conventional radiology reports. Just those graphs with affirmation by the legitimate report were remembered for the examination. Graphs were then surveyed for other relevant information identified with the injury. The study was conducted on 521 patient's male and female ages from 15 to 56 to find out the rate of frontal bone injury. Data has been collected with the consent of the patient.

## DATA COLLECTION:

The clinical moral audit committee of trustees evaluated and approved the

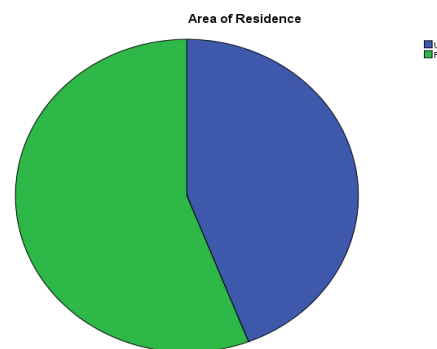
**Table 1: Cause of Head Injury**

	Frequency	Percentage	Valid Percentage
Fire Arm Injury	158	29.0	30.3
Violent Assault	209	38.4	40.1
Road Traffic Accident	67	12.3	12.9
Fall From Height	24	4.4	4.6
Sports Injury	37	6.8	7.1
Industrial Injury	26	4.8	5.0
Total	521	95.8	100.0

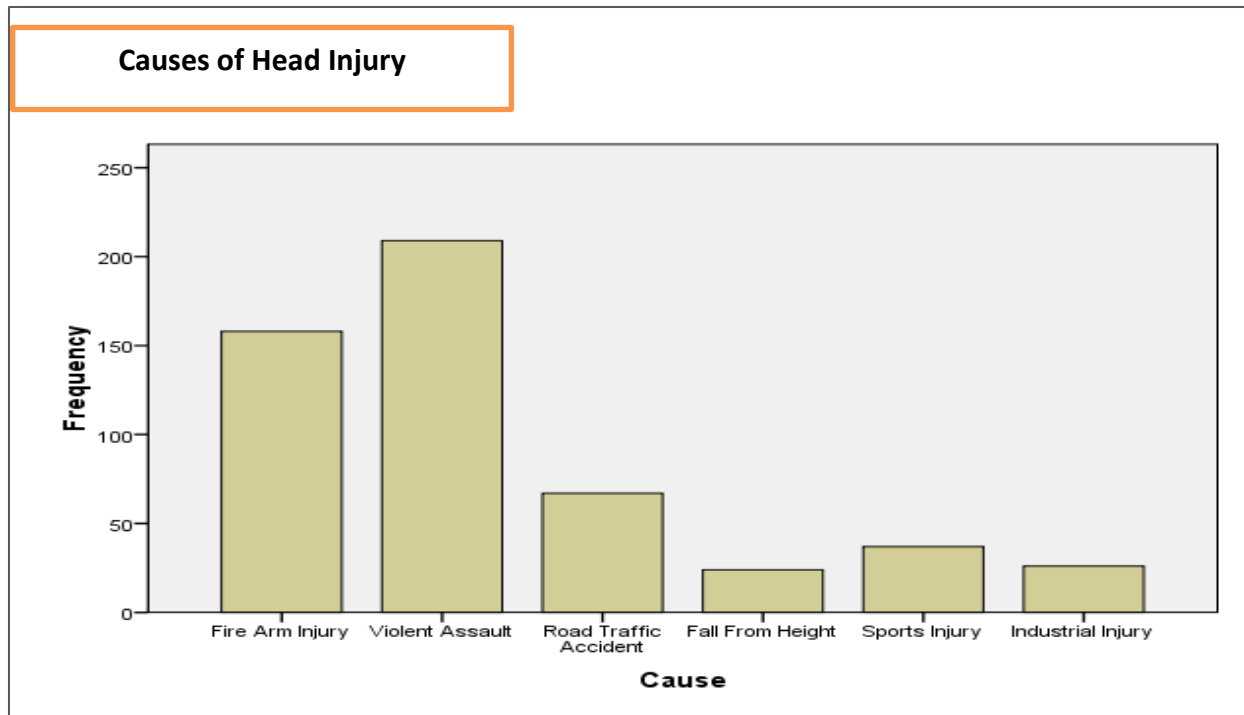
examination procedure prior to the start of the evaluation, and each patient gave informed consent. Proforma content has been gathered and is presented in table format, with the version of the software used to evaluate it (SPSS) 17. For quantitative characteristics such as age, the mean and standard deviation were calculated.

## RESULTS:

The 521 number of patients were included in this study from 18 years to 56 old patients. In which the majority of patients are from rural dwellers 291 (55.9%) than urban dwellers 230 (44.1%) correspondingly.



Area of Residence					
		Frequency	Percent	Valid Percent	Cumulative Percent
Valid	Urban	230	44.1	44.1	44.1
	Rural	291	55.9	55.9	100.0
	Total	521	100.0	100.0	



The total number of cases of head injury in year 2019 was 521 cases, and cause of those are illustrated in Table 1. Out of those cases violent head injury was the common cause of head injury in patients 209 (38.4%).

		Frequency	Percentage	Valid Percent
Valid	Frontal Bone	217	39.9	41.7
	Temporal Bone	139	25.6	26.7
	Occipital Bone	60	11.0	11.5
	Parietal Bone	49	9.0	9.4
	Nasal Bone	56	10.3	10.7
	Total	521	95.8	100.0

The 521 patients in which most injured cranial bone is Frontal bone 217 (39.9%) which is illustrated in Table 2.

#### DISCUSSION:

Frontal bone injuries are common and happen in of maxillofacial injuries and have a higher level or occurrence whenever contrasted with the rest of the sorts of break including the maxillofacial locale.<sup>4</sup>

The frontal bone in a grown-up is an unpaired bone that is an aspect of the boney structure that frames the foremost and prevalent bits of the skull. Toward the start of life, it is a bone isolated by a transitory stitch called the frontal stitch. It at that point changes into a solitary front bone, missing the stitch much of the time. All through life, it assumes a fundamental part in ensuring significant neural structures and structures the prevalent

part of the circle. Frontal bone cracks happen in generally 5% to 15% of every single facial break. In our study we collected the data of 521 patients and analyze the most cause of injured bone was violent assault and which cranial bone highly injured is frontal bone.

As the frontal bone is the most foremost neurocranium bone in the skull, it is flanked by both the encompassing neurocranial bones and the most prevalent viscerocranial bones.<sup>5</sup>

Frontal bone breaks can be detached facial wounds or can broaden intracranially. The frontal sinus has a foremost and back divider. Breaks to the foremost plate alone are facial wounds, requiring restorative careful treatment whenever discouraged.<sup>6-8</sup>

Breaks to the back plate are calvarial wounds and convey a few dangers, including intracranial disease (from defilement of the cerebrospinal liquid with no sterile air and liquid from the frontal sinus), intracranial drain, and direct horrendous mind injury if crack parts are extended posteriorly. Assess for frontal sinus injury first utilizing bone windows and afterward utilizing cerebrum windows. This is justifiably so as skull base wounds are regularly ignored while treating more dangerous wounds in Emergency Departments. Notwithstanding, it ought to be recalled that Frontal bone fracture can prompt genuine long haul horribleness and sequelae. In this manner over and over we ought to be reminded to altogether look at our patients in any conditions we are in.

#### **CONCLUSION:**

The results of the study highlight that most of the patients are from rural and among them, the most common cause of head injury is violent assault and mostly injured cranial bone injury is frontal bone.

#### **ACKNOWLEDGEMENT:**

All praises to Almighty Allah, Omniscient and omnipresent who bestowed upon me patience and ethical courage to conclude and undertake this research study. Firstly I would like to state my thanks to Allah almighty. He isn't the one and merely who saves me but He is a great companion and loyal. He remains on my side, He bestows strength and provides me marvelous blessing that I never give up and rise up again and again.

I would like to convey appreciation to co-authors for their understanding, patience and also their motivating assistance helped me finishing this research article.

#### **CONFLICT OF INTEREST:**

No competing interest declared.

**ETHICS APPROVAL:** The ERC gave ethical review approval

**CONSENT TO PARTICIPATE:** written and verbal consent was taken from subjects and next of kin

**FUNDING:** The work was not financially supported by any organization. The entire expense was taken by the authors

**ACKNOWLEDGEMENTS:** We would like to thank the all contributors and staff and other persons for providing useful information.

**AUTHORS' CONTRIBUTIONS:** All persons who meet authorship criteria are listed as authors,

and all authors certify that they have participated in the work to take public responsibility of this manuscript. All authors read and approved the final manuscript.

**CONFLICT OF INTEREST:** No competing interest declared.

#### **REFERENCES:**

1. Gerbino G, Rocchia F, Benech A, Caldarelli C. Analysis of 158 frontal sinus fractures: current surgical management and complications. *Journal of cranio-maxillofacial surgery*. 2000 Jun 1;28(3):133-9.
2. Piotrowski WP. The primary treatment of frontobasal and midfacial fractures in patients with head injuries. *Journal of oral and maxillofacial surgery*. 1992 Dec 1; 50(12):1264-8.
3. Bell RB, Dierks EJ, Brar P, Potter JK, Potter BE. A protocol for the management of frontal sinus fractures emphasizing sinus preservation. *Journal of oral and maxillofacial surgery*. 2007 May 1; 65(5):825-39.
4. Kerman M, Cirak B, Dagtekin A. Management of skull base fractures. *Neurosurgery Quarterly*. 2002 Mar 1; 12(1):23-41.
5. Katzen JT, Jarrahy R, Eby JB, Mathiasen RA, Margulies DR, Shahinian HK. Craniofacial and skull base trauma. *Journal of Trauma and Acute Care Surgery*. 2003 May 1; 54(5):1026-34.
6. Katzen JT, Jarrahy R, Eby JB, Mathiasen RA, Margulies DR, Shahinian HK. Craniofacial and skull base trauma. *Journal of Trauma and Acute Care Surgery*. 2003 May 1; 54(5):1026-34.
7. Oryan A, Monazzah S, Bigham-Sadegh A. Bone injury and fracture healing biology. *Biomedical and environmental sciences*. 2015 Jan 1; 28(1):57-71.
8. Perry M. Maxillofacial trauma— Developments, innovations and controversies. *Injury*. 2009 Dec 1; 40(12):1252-9.
9. Andrew TW, Kalaverozos N. Injuries of the Facial Skeleton. *Textbook of Plastic and Reconstructive Surgery*. 2016 Aug 2:208.
10. Cultrera F, Giuffrida M, Mancuso P. Delayed post-traumatic frontal sinus mucopyocoele presenting with meningitis. *Journal of Cranio-Maxillofacial Surgery*. 2006 Dec 1; 34(8):502-4.