

## ORIGINAL ARTICLE

# Midshaft Femur Fracture Treated with Interlocking Nail; Our Experience

Zahoor Illahi Soomro\*, Badaruddin Sahito\*\*, Zulfiqar Ali Soomro\*\*\*, Zamir Ahmed Soomro\*\*\*\*,  
Abdul Sami Mirani\*\*\*\*\*, Azizullah Bhayo\*\*\*\*\*

## ABSTRACT

**Objective:** The objective of this study is to assess the outcome of midshaft femur fracture treated with interlocking nail.

**Methods:** This prospective study conducted at the department of orthopaedic surgery at multiple tertiary care hospitals of Sindh from January 2015 to December 2017. A total number of 63 patients were recruited in this study. The inclusion criteria was all adult patients of either sex with midshaft femur fracture, multiple long bones fractures, polytrauma cases. The patients with pathological fractures, cases with neuromuscular disorder, open contaminated fractures, and metabolic bone disorder were excluded from this study. All the data was collected on a proforma designed for this study and the results were statistically analyzed.

**Results:** Sixty three patients with midshaft femur fracture were included in the study with mean age as 36.25 years. Most of the patients were in age group 18-30 years (n=26, 41.3%) followed by 21 patients in 31-50 years (33.3%) and 16 patients in 51-60 years (25.4%), Forty seven were males (75%) and sixteen were females (25%). Majority of the patients had right side affected (56%) whereas 44% of the patients had left side affected. Forty three percent of the patients had transverse fracture followed by oblique and comminuted (21%) and spiral (16%). Patients with open fracture, segmental fracture, bilateral femur fractures and pathological fractures were excluded from the study. Due to high velocity trauma these injuries were associated with clavicle fracture in 5 patients, ipsilateral patella in 3 and tibial plateau fracture in 4 patients. All patients were treated with interlocking nail. Fifty patients fracture united within 4 to 6 months 6 patients fracture united in 6 to 12 months, fractures not united in 4 patients and treated with other methods and three patients loss the follow up after 2 months. Knee range of motion was 90 degree in 7 patients and 90-120 degree motion range in 53 patients. Superficial infection at operative site occur in 3 patients that treated with antibiotics and recovered uneventful.

**Conclusion:** The interlocking nailing in mid shaft femur fractures was ideal method of fixation with excellent to good results in terms of union and early weight bearing.

**Key Words:** Femur, Midshaft Fracture, Interlocking Nail.

**Article Citation:** Soomro ZI, Sahito B, Soomro ZA, Soomro ZA, Mirani AS, Bhayo A. Midshaft Femur Fracture Treated with Interlocking Nail; Our Experience. J Peoples Uni Med Health Sci. 2018;8(3):253-7.

## INTRODUCTION:

Due to high speed accidents midshaft femur fractures are frequent injuries associated

- \* Assistant Professor, Deptt. of Orthopaedic Surgery PUMHSW-SBA
- \*\* Associate Professor, Deptt. of Orthopaedic Surgery, DUHS & Civil Hospital Karachi.
- \*\*\* Assistant Professor, Deptt of Orthopaedic Surgery, GMMMC Sukkur.
- \*\*\*\* Assistant Professor, Deptt. of Orthopaedic Surgery, SMBBMU, Larkana
- \*\*\*\*\* Assistant Professor, Surgical Deptt, GMMMC Sukkur.
- \*\*\*\*\* Assistant Professor, Deptt. of Orthopaedic Surgery, GIMS, Gambat.

### Correspondence to:

**Dr. Zahoor Illahi Soomro**

Assistant Professor, Dept. of orthopaedic Surgery  
PUMHSW-SBA.  
Email: zisoomro786@yahoo.com

with significant morbidity and less mortality<sup>1</sup>. Midshaft femur fractures occur in all age groups but less in geriatric patients<sup>2</sup>. Femur is the main load bearing bone. In the past, definitive treatment of diaphyseal femur fractures with a cast or brace has been attempted, particularly in the developing world where resources are limited. Furthermore, maintenance of proper length, alignment, and rotation was quite difficult with cast treatment<sup>3</sup>. Close reduction and intramedullary interlocking nail is standard procedure for diaphyseal femur fractures<sup>4</sup>. It is attractive method of treating long bones<sup>5</sup>. In 1980 interlocking nail was invented<sup>6</sup>. Before that invention K-nail used during the 2<sup>nd</sup>



world war for femur fracture fixation. Use of other methods treating diaphyseal femur fracture like traction, plating are declined due to better results with interlocking nail<sup>7</sup>. Intramedullary nailing has several advantages compared with other methods of stabilization for fractures of femur shaft. Over the past three decades, IM nailing has become the standard of care for most diaphyseal femur fractures- not only in developed countries but also in the developing world. Intramedullary nailing is extremely effective and has a high rate of success in achieving union; restoring proper length, alignment, and rotation; and allowing early mobilisation and weight bearing. Other advantages of locked intramedullary nailing include immediate joint mobilisation, early muscles rehabilitation, decreased hospital length of stay, and early return to work. Furthermore, IM nailing offers the advantage of immediate weight bearing. Incidence of midshaft femur (25%) fracture was 1/100000 in Swedish registry but it may be high in our society<sup>8</sup>. Advantages of interlocking nail are small scar, less blood loss, early mobilization, and faster healing<sup>9</sup>. The risk of nonunion after nailing in femur fracture is 0.5% to 12.5%<sup>10</sup>.

The vast majority of patients who undergo intramedullary nail fixation of a femoral shaft fracture regain excellent functional outcomes and normal knee and hip range of motion. Keeping all the above facts in view, we conduct this study to assess the outcome of midshaft femur fracture treated with interlocking nail in our setup.

## METHODS:

This prospective study was conducted in the department of Orthopaedic Surgery at multiple tertiary care Hospitals of Sindh from January 2015 to December 2017. A total number of 63 patients were recruited in this study. All

adult patients of either sex with midshaft femur fracture, multiple long bones fractures, polytrauma cases were included and the Patients with pathological fractures, cases with neuromuscular disorder, open contaminated fractures, and metabolic bone disorder were excluded from this study. All the data obtained was collected on a proforma designed for this study and the results were statistically analysed and tabulated.

## RESULTS

Sixty three patients with midshaft femur fracture were included in the study with mean age as 36.25 years (Fig I). Most of the patients were in age group 18-30 years (n=26, 41.3%) followed by 21 patients in 31-50 years (33.3%) and 16 patients in 51-60 years (25.4%), Forty seven were males (75%) and sixteen were females (25%) (Fig II).

Majority of the patients had right side affected (56%) whereas 44% of the patients had left side affected. Forty three percent of the patients had transverse fracture followed by oblique and comminuted (21%) and spiral (16%). Patients with open fracture, segmental fracture, bilateral femur fractures and pathological fractures were excluded from the study. Due to high velocity trauma these injuries were associated with clavicle fracture in 5 patients, ipsilateral patella in 3 and tibial plateau fracture in 4 patients. All patients were treated with interlocking nail. Fifty patients fracture united within 4 to 6 months 6 patients fracture united in 6 to 12 months, fractures not united in 4 patients and treated with other methods and three patients loss the follow up after 2 months. Knee range of motion was 90 degree in 7 patients and 90-120 degree motion range in 53 patients. (Table I) Superficial infection at operative site occur in 3 patients that treated with antibiotics and recovered uneventful.

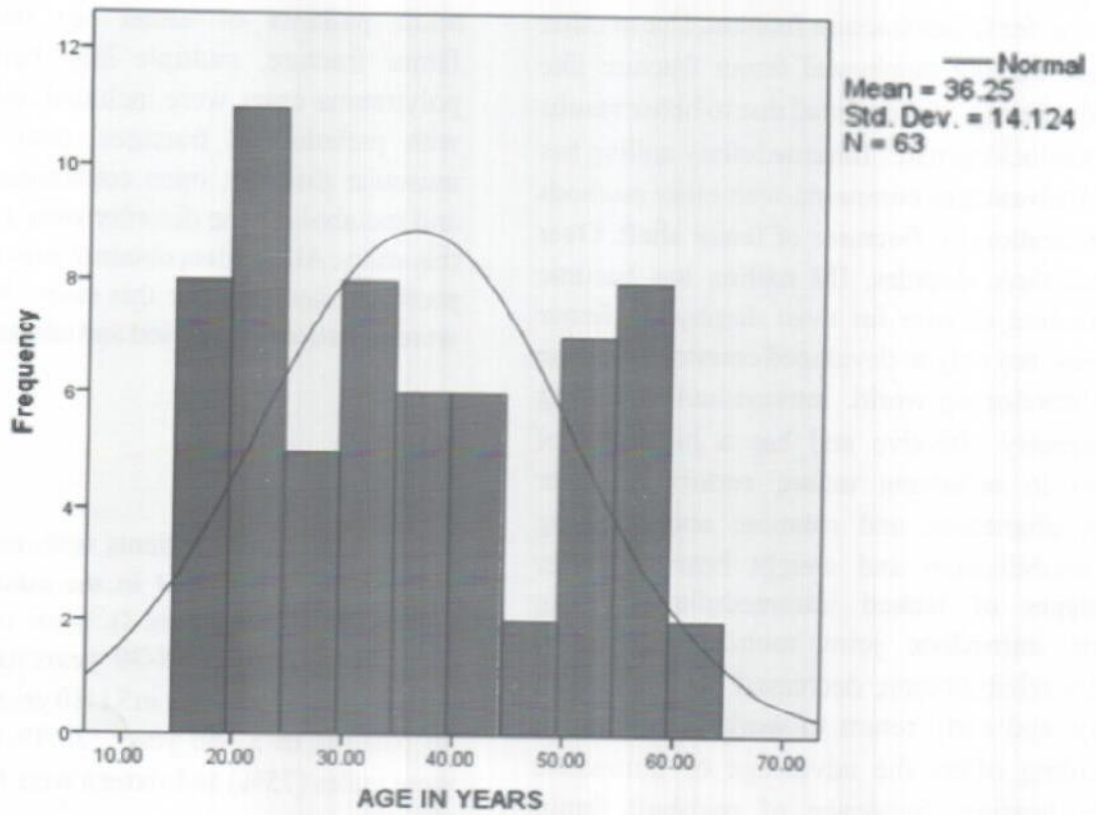


Fig-I: Age Distribution

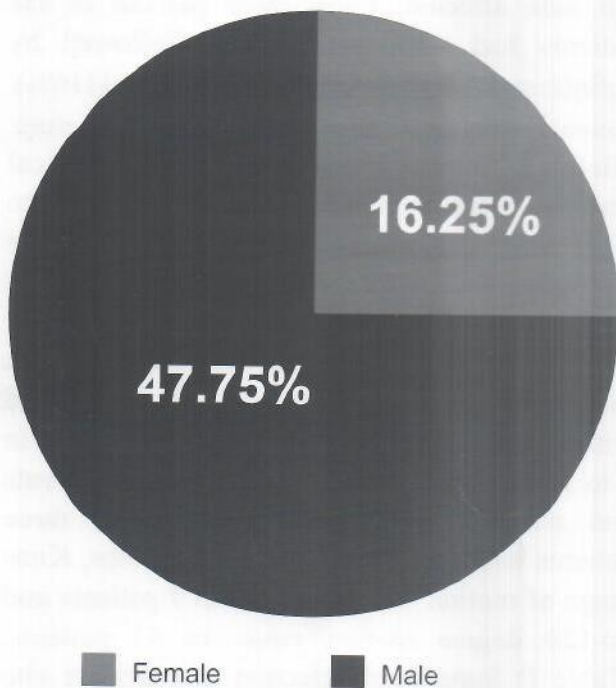


Fig-II: Frequency Distribution of Gender

Table I. Characteristics of Fracture Patients

Variables	n	%
<b>Affected side</b>		
Left	28	44.4
Right	35	55.5
<b>Type of Fracture</b>		
Transverse	27	42.9
Oblique	13	20.6
Spiral	10	15.9
Comminuted	13	20.6
<b>Associated Injuries</b>		
Clavicle fracture	5	7.9
Ipsilateral patella	3	4.7
Tibial plateau fracture	4	6.3
<b>Union Time</b>		
4-6 months	50	79.3
6-12 months	6	9.5
<b>Knee Range of Motion</b>		
90 degree	7	11.1
90-120 degree	53	84.1



**DISCUSSION:**

Paschoal FM et al: treated 103 patients with femoral fractures . 97.9% united with average 16.72 weeks and 3% nonunited with less risk of infection<sup>11</sup>.

Study conducted in India; treated 30 cases with diaphyseal femur fracture in three years . 63 % have transverse fracture . 96.6 % united with mild infection and shortening in 4 patients with 2 cases delayed union . 86.6% showed excellent to good results<sup>12</sup>.

Retrospective analysis of 500 patients treated with closed diaphyseal femur fracture treated with SIGN nail showed > 5 degree malalignment in 51 patients (10%) and 10 degree in 8 patients (1.6%) with variability at the fracture site<sup>13</sup>.

Study conducted at Tamaka ; out of 60 patients 47 cases (78.3% ) showed excellent and 12 cases (20%) good results and poor in 1.7% according to modified Thoresen<sup>14</sup>.

Yong Gang et al; analysed 425 patients with femur shaft fracture only 2.5 % patients develop nonunion with closed intramedullary nailing<sup>15</sup>.

A comparative study conducted at Kathmandu; showed mean time for union in plating 19.4 weeks as compared to nailing 14.78 weeks. 23 (38.3%) excellent , five (8.3%) good and two (3.3%) poor results in nail group and 15 (25.5%) excellent , 9 (15%) good and one (1.7%) fair and 5 (8.3%) poor in plating patients. This study showed no significant difference<sup>16</sup>.

A review of 47 cases, showed range of motion >110 degrees in all patients except one with 95 degree range of motion after physiotherapy<sup>17</sup>.

44 patients treated with interlocking nail, 40 ( 90.9%) united completely and 4(9.1%) patient develop nonunion. 28 patient had knee flexion of 120 degree and above ; 12 patient with knee flexion between 90-120 degree and 4 patient below 90 degree flexion<sup>18</sup>.

Study conducted at Nagpur; treated femur diaphyseal fracture with open in 110 cases and closed in 162 cases. Complete union occurred in 262 patients with knee full flexion > 90 % cases, 8 % showed 0-120 degree flexion and 2 % 0-90 degree flexion<sup>19</sup>.

Study conducted in Lahore, showed excellent results in 13 patients, good in 9, fair in 2 and 1 poor with mean time of fracture healing was 14.3 weeks<sup>20</sup>.

**CONCLUSION:**

We concluded that interlocking nail in diaphyseal femur fracture revolutionize the method of fixation. It has less complications with excellent to good results in respect to union, early weight bearing, and range of motion.

**REFERENCES:**

1. Holena D, Stoddard D, Martin ND. Clinical outcomes following invasive versus noninvasive preoperative stabilization of closed diaphyseal femur fractures. *Eur J Trauma Emerg Surg.* 2012;38:623-6.
2. Bumpass DB, Ricci WM, McAndrew CM. A prospective study of pain reduction and knee dysfunction comparing femoral skeletal traction and splinting in adult trauma patients. *J Orthop Trauma.* 2015;29:112-8.
3. Kumar J, Shafique A, Umer M. Functional outcome of diaphyseal fractures of femur managed by locked intramedullary nailing in adults. *JPOA.* 2013;25(1):38-42.
4. Santolini E, West R, Giannoudis PV. Risk factors for long bone fracture non-union: a stratification approach based on the level of the existing scientific evidence. *Injury.* 2015;46(8):8-19.
5. Gary JL, Munz JW, Burgess AR. Push-past reaming as a reduction aid with intramedullary nailing of meta diaphyseal and diaphyseal femoral shaft fractures. *Orthopaedics.* 2014;37(6):393-6.
6. Larsen P, Elsie R, Graven-Nielsen T. Decreased muscle strength is associated with impaired long-term functional outcome after intramedullary nailing of femoral shaft fracture. *Eur J Trauma Emerg Surg.* 2015;41:673-81.
7. Shah RK. Nonunion following intramedullary aniling of femoral shaft fractures in low income countries. *I Med Pub J.* 2016;2(22):1-3.
8. Patel NM, Yoon RS, Koerner JD. Timing of diaphyseal femur fracture nailing: is the



- difference night and day? *Injury*. 2014; 45:546-9.
9. Fantry AJ, Ellia G, Vopat BG, Daniels AH. Distal femoral complications following antegrade intramedullary nail placement. *Ortho Rev (Pavia)*. 2015;7(1):5820. doi: 10.4081/or.2015.5820.
  10. Vallier HA, Dolenc AJ, Moore TA. Early appropriate care: a protocol to standardize resuscitation assessment and to expedite fracture care reduces hospital stay and enhances revenue. *J Orthop Trauma*. 2016;30(6):306-11.
  11. Paschoal FM, Paccola CAJ. Ribeirão Preto school of medicine locking nail: Clinical experience in the femoral fractures treatment . Paschoal FM, Paccola CAJ, *Acta orthop Bras* ; 2000; 8(4):160-77.
  12. Deepak MK, Jain K, A Rajamanya K, Partik R, Rupakumar , Ravishankar. Functional outcome of diaphyseal fractures of femur managed by closed intramedullary interlocking nailing in adults. *A Afri Med*; 2012; 11(1):52-7.
  13. Carsen S, Si-Hyeong S, Simon D, Feibel R. Treatemnt with the SIGN nail in closed diaphyseal femur fractures resukts in acceptable radiographic alignment. *Clin Orhtop Relat Res*. 2015; 47(3): 2394-2401.
  14. Mukherjee D. A comparative study of management of fracture shaft of femur by open versus closed intramedullary interlocking nailing. *I Med Gazette*. 2015;190-5.
  15. Yong-Gang MA, Ge-Liang Hu, Wei Hu, Fan Liang. Surgical factors contributing to nonunion in femoral shaft fracture following intramedullary nailing. *Chinese J Traumat*. 2016;19:10-12.
  16. Thapa S, Thapa SK, Dhakal S, Marsini R, Hamal B, Rai RK, et al. A comparative study of fracture shaft of femur in adults treated with broad dynamic compression plate versus intramedullary interlocking nail *JCMS-Nepal*. 2016;12(2); 66-9.
  17. Swamy A, Swamy A. Interlocking nailing of femoral diaphyseal fractures: A review of 47 cases. *Int. J Pharma Sci Invention*. April 2013; 2 (4):20-3.
  18. Burc H, Atay T, Demirci D, Baykal YB, Kirdemir V, Yorgancigil H. The intramedullary nailing of adult femoral shaft fracture by the way of open reduction is a disadvantage or not? *Indian J Surg*. 2015;77(2):583-88.
  19. Kimmatkar N, Hemnani JT, Hemnani TJ, Jain SK. Diaphyseal femoral intramedullary nailing : closed or open intervention? *Int J Sci Study*. Feb 2014;1(1):15-8.
  20. Qureshi ZA, Shah WAS, Kumar J, Yousaf A. Management of diaphyseal femur fractures in adults with intramedullary interlocking nail. *Biomedica*. 2012;28:117-20.