

# Ligature Materials and postmortem Findings in Hanging Cases Brought for Autopsy at a Tertiary Care Hospital of Sindh, Pakistan

Salman Ahmed Farsi Kazi, Waheed Ali Nayhoon, Shahid Kamran, Amna Mangi,  
Ishrat Bibi, Jamshed-ul-Qadir Memon,

## ABSTRACT

**Objective:** To study the ligature materials and postmortem findings in hanging cases brought for autopsy at a tertiary care hospital of Sindh, Pakistan

**Methods:** The current retrospective study was conducted in the department of Forensic Medicine and Toxicology LUMHS Jamshoro, Hyderabad and Medico-legal section of Liaquat University Hospital Hyderabad, study covers the duration of August 2014 to July 2017.

A sample of 100 autopsy cases was selected according to criteria of inclusion and exclusion. Ligature material used and postmortem examination findings were noted in a preformed Proforma. Data variables were noted, compiled, tabulated and analyzed on Excel sheet. Study variables were analyzed by descriptive statistics.

**Results:** Of 100 autopsy cases, male were 83% and 17% were female. Majority of cases belonged to fourth decade (38%). Ligature mark was categorized as above, at the level and below the level of thyroid cartilage were noted in 94%, 2% and 4% of cases respectively ( $P=0.001$ ). Nylon rope (42%), jute rope (16%) and cotton rope (11%) were most common in male while cotton Dopatta (7%) was common among female. Tongue protrusion (81%), bluish discoloration (79%), petechiae (71%) and salivary stains (37%) were common noted postmortem findings.

**Conclusion:** The present study reports nylon rope as most common ligature in male and cotton dopatta in female. Tongue protrusion, bluish discoloration, petechiae and salivary stains were prominent postmortem findings.

**Key Words:** Autopsy, Hanging, Ligature, Postmortem Findings

**Article Citation:** Kazi SAF, Nayhoon WA, Kamran S, Mangi A, Bibi I, Memon JQ. Ligature Materials and postmortem Findings in Hanging Cases Brought for Autopsy at a Tertiary Care Hospital of Sindh, Pakistan J Peoples Uni Med Health Sci. 2018;8(3):145-50.

## INTRODUCTION:

Hanging is widely used way of committing suicide. It is a type of asphyxial death. Hanging is defined as asphyxial death caused by suspension of a ligature around neck in which the constricting force is weight of the body<sup>1</sup>. The symptoms of hanging include subjective sensations such as

the ringing in ears, light flashes and loss of consciousness. Death is very rapid in hanging hence it is termed as a painless way of death<sup>2</sup>. Estimates of World Health Organization (WHO) show approximately 900,000 hanging cases that die globally per annum<sup>3</sup>. Subjective thought of hanging oneself comes progressively or as an impulse<sup>4</sup>. Hanging is adopted as a last resort of getting relief from the grievances in suicidal cases when other forms have failed such as the poisoning or cutting the throat deliberately. Hanging is a leading cause of asphyxial deaths particularly in suicidal cases<sup>5</sup>. Hanging, being easy method, is commonest way of committing suicide for those who wish no more living<sup>6</sup>. Hanging is easy in sense that a slight force is sufficient to cause painless death within seconds. Constricting force may be whole body weight in cases of complete hanging or weight of the head in cases of

- \* Associate Professor, Deptt of Forensic Medicine & Toxicology, FM&AMS, Isra University Hyderabad.
- \*\* Associate Professor, Deptt. of Forensic Medicine & Toxicology, LUMHS, Jamshoro.
- \*\*\* Assistant Professor, Deptt. of Forensic Medicine & Toxicology, Al-Tibri Medical College, Karachi
- \*\*\*\* Lecturer, Deptt. of Forensic Medicine & Toxicology, LUMHS, Jamshoro.

### Correspondence to:

**Dr. Salman Ahmed Farsi Kazi**

Associate Professor, Deptt. of Forensic Medicine & Toxicology, FM&AMS, Isra University Hyderabad.  
Email: drsalmanakazi@gmail.com



incomplete/partial hanging. In cases of partial hanging, only the head and chest are off the ground. Partial hanging shows the toes or feet are often touching the ground and rest of body is lying on the ground. Kneeling down is observed in partial hanging<sup>6</sup>. The present is a retrospective study showing the patterns of cervical injury in hanging cases brought for autopsy at our tertiary care hospital. In addition, we attempted to include demographic characters of gender and age of hanging cases.

#### METHODS:

The present retrospective study was carried out in the Forensic Medicine and Toxicology LUMHS Jamhoro, Hyderabad and Medico-legal section of Liaquat University Hospital Hyderabad. The study covers the duration of August 2014 to July 2017. Ethical approval was taken in advance from the Institute's Ethical Committee. Protocol was elaborated before conducting the study. Records of autopsy cases of hanging were observed. Of 340 autopsy cases, a sample of 100 autopsy cases was sorted for the study purpose according to criteria of inclusion and exclusion. All autopsies of alleged history of hanging qualified for inclusion while violent asphyxial deaths other than hanging were excluded. Emergency records, Notes of medicolegal officers, police notes and file records were observed. Age, gender, level of ligature material, type of ligature material and types of hanging and post mortem examinations findings were noted in a preformed Proforma. Police papers, inquest reports, hospital records and autopsy findings were keenly observed to fulfill the inclusion criteria. Collected data variables were noted in a pre- structured proforma. Data was compiled, tabulated and analyzed on Excel sheet. Study variables were analyzed by descriptive statistics. Continuous variables (age) were analyzed by Student's t-testing. Categorical variables (gender) were cross tabulated and the results presented as frequency and %.

#### RESULTS:

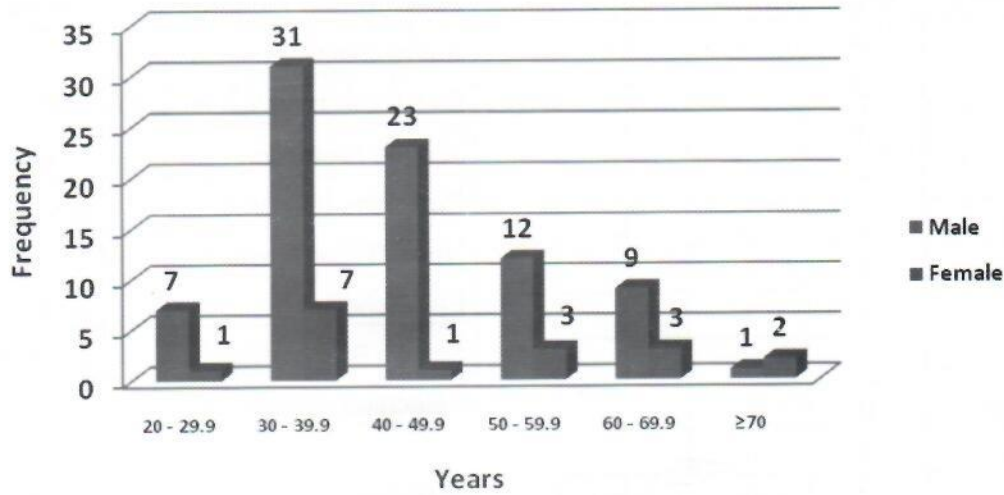
Of 100 autopsy cases, male were 83% and

17% were female. Male to female (M: F) ratio was calculated as 4.88:1. Mean ( $\pm$ SD) age of total sample was  $40.1 \pm 13.5$  years for both genders. Majority of cases belonged to fourth decade (38%), followed by fifth decade (24%) and sixth decade (15%) ( $P=0.0001$ ) (Table-I and graph-I). Table-II shows the complete and incomplete hanging noted in 82% and 18% of cases respectively ( $P=0.0001$ ) (Graph-II). Table-III shows the level of ligature mark was categorized as above, at the level and below the level of thyroid cartilage were noted in 94%, 2% and 4% of cases respectively ( $P=0.001$ ). This shows majority of cases were having ligature mark above the thyroid cartilage. Hyoid or thyroid cartilage fracture was not observed in the present study. Table-IV shows the type of ligature material used by hangers. Nylon rope (42%), jute rope (16%) and cotton rope (11%) were most common in male while cotton Dopatta (7%) was common among female (graph-IV). Post mortem examination findings of victims are summarized in table-V (graph-V). Tongue protrusion (81%), bluish discoloration (79%), petechiae (71%) and salivary stains (37%) were common noted postmortem findings (Graph-V).

**Table I. Distribution of Age and Gender of Autopsy Cases (n=100)**

Age (Years)	Male	Female	Total
20 - 29.9	7	1	8
30 - 39.9	31	7	38
40 - 49.9	23	1	24
50 - 59.9	12	3	15
60 - 69.9	9	3	12
$\geq 70$	1	2	3
Total	83	17	100

### Age distribution



Graph I. Age Frequency of Autopsy Bodies

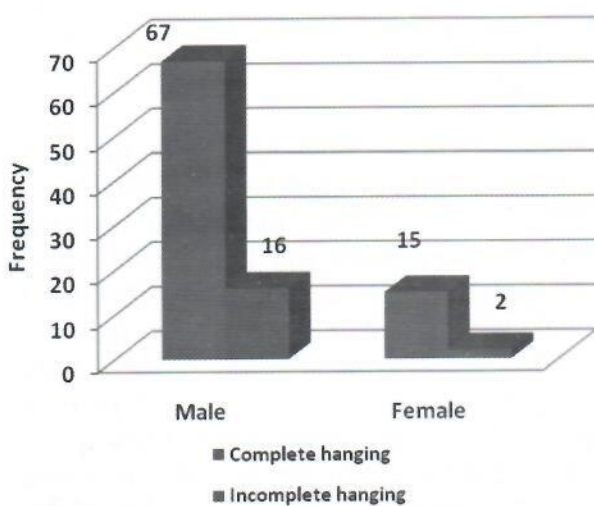
Table II. Types of Hanging (n=100)

Hanging Types	Male	Female	Total
Complete Hanging	67	15	82
Incomplete Hanging	16	2	18
Total	83	17	100

Table III. Level of Ligature Mark (n=100)

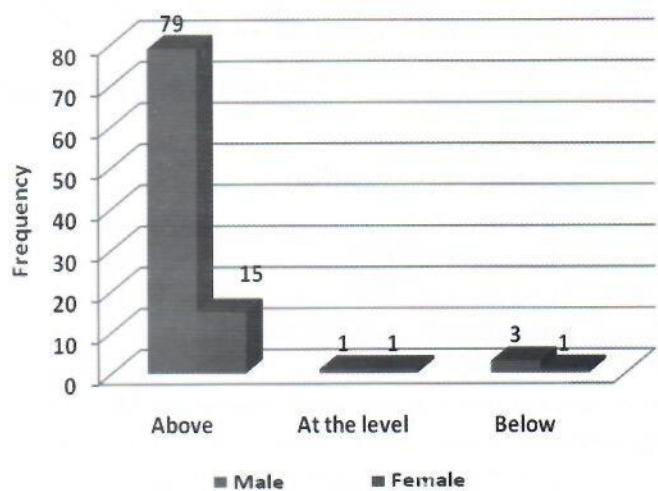
Thyroid Cartilage	Male	Female	Total
Above	79	15	94
At the Level	1	1	2
Below	3	1	4
Total	83	17	100

### Types of Hanging



Graph II. Frequency of Types of Hanging

### Level of Ligature mark



Graph III. Frequency of Level of Ligature Mark

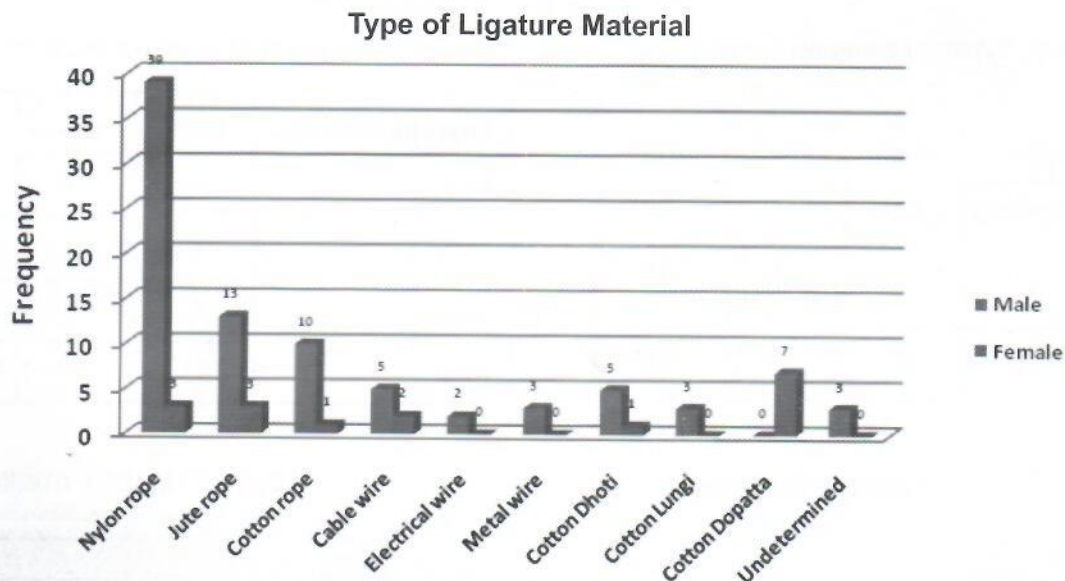


**Table IV. Types of Ligature Material (n=100)**

Ligature Material	Male	Female	Total
Nylon rope	39	3	42
Jute rope	13	3	16
Cotton rope	10	1	11
Cable wire	5	2	7
Electrical wire	2	0	2
Metal wire	3	0	3
Cotton Dhoti	5	1	6
Cotton Lungi	3	0	3
Cotton Dopatta	0	7	7
Undetermined	3	0	3
Total	83	17	100

**Table V. Postmortem Examination Findings of Victims (n=100)**

Postmortem Findings	Male	Female
Saliva Stains	37	13
Bluish Discoloration (lips, fac)	79	15
Tongue Protrusion	81	13
Petechiae (Conjunctiva)	71	12
Nose/Throat Bleeding	3	13
Ear Bleeding	9	5
Semen Stains	11	0
Petechiae (Scalp)	12	9
Feet Planter Flexed	10	10
Feces	13	11



**Graph IV: Type of Ligature Material**

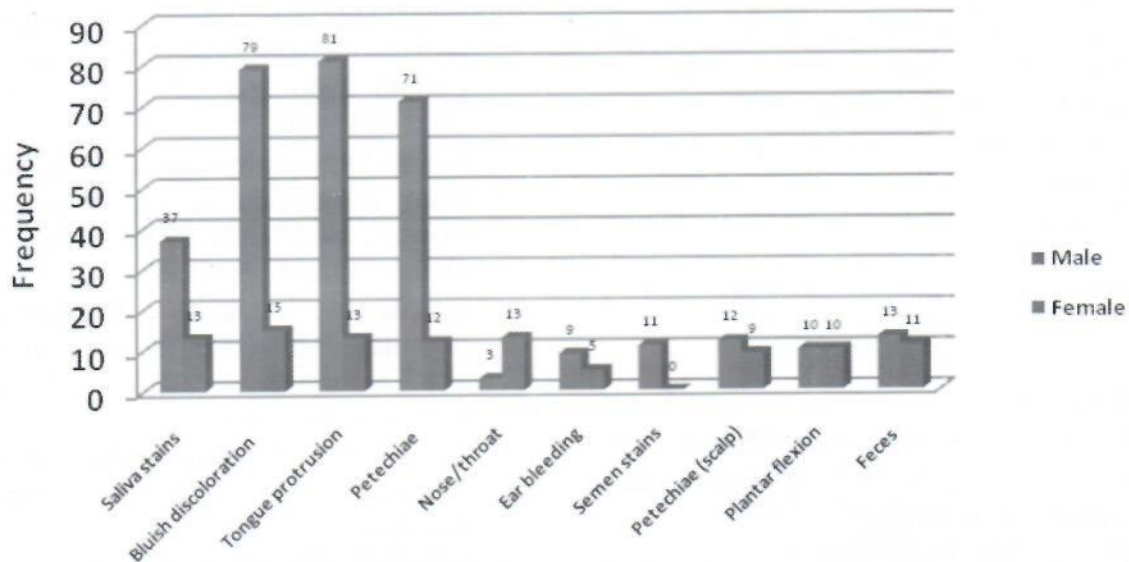
**DISCUSSION:**

In this retrospective study cases of autopsies of alleged history of hanging were included. The age, gender, level of ligature material, type of ligature material and types of hanging and post mortem examinations findings were collected. Of 340 autopsy cases, a sample of 100 autopsy cases was sorted out that fulfilled the inclusion criteria. Of 100 autopsy cases, male were 83% and 17% were female. Male to female (M: F) ratio was calculated as 4.88:1. Mean (±SD) age of total sample was 40.1±13.5 years for both genders.

The findings are in agreement with previous studies<sup>7-10</sup>. The male gender finding of 83% is in agreement with a recent study<sup>11</sup> that reported 85% victims were males and 15% victims were female. Shrivastava et al<sup>7</sup> reported 137(67.5%) were male victims and 66 (32.5%) were females, the findings are discordant to the present study as male were noted in 83% of cases. This may be due to different geographical areas and social values. In present study, the majority of cases belonged to fourth decade (38%), followed by fifth decade (24%) and sixth decade (15%)



## Post mortem examination findings



**Graph V: Postmortem Examination Findings**

( $P=0.0001$ ) (Table 1 and graph 1). Waghmode et al<sup>11</sup> reported similar age categories of 4<sup>th</sup> decade (33.33%), followed by 5<sup>th</sup> (18.33%) and 6<sup>th</sup> decade (17.5%). Our findings are also concordant with a previous study<sup>12</sup> that reported similar age categories. However a recent study by Shrivastava et al<sup>7</sup> have reported 3<sup>rd</sup> decade as common (24.1%) and 2<sup>nd</sup> decade in female (12.3%). This is in contrast to present and previous studies<sup>8-10</sup>. In present study, the majority of victims belonged to 3<sup>rd</sup> decade among males were 49 (24.1%), followed by 4<sup>th</sup> decade were 44 (21.7%) while 2<sup>nd</sup> decade was most common among females were 25 (12.3%), followed by 3<sup>rd</sup> decade were 24 (11.8%). In present study, the complete and incomplete hanging noted in 82% and 18% of cases respectively ( $P=0.0001$ ) (Graph-II). The findings are in agreement with recent study of Waghmode et al<sup>11</sup> that reported complete hanging in 75% victims and partial hanging in 30(25%) victims. Our finding is also supported by previous study of Shaikh et al.<sup>13</sup> However, recent study of Shrivastava et al<sup>7</sup> reported typical hanging 12.3% cases while atypical hanging in 72.4% of cases. In present study, the level of ligature mark above, at the level and below the level of thyroid cartilage was noted in 94%, 2% and 4% respectively ( $P=0.001$ ). This shows

majority of cases were having ligature mark above the thyroid cartilage. The findings are in agreement with Waghmode et al<sup>11</sup> that reported in 87.5% cases the ligature mark above the level of thyroid cartilage. Our findings of ligature mark are also in agreement previous studies<sup>14,15</sup>. In present study, the nylon rope (42%) was most common followed by jute rope (16%) and cotton rope (11%) in male while cotton Dopatta (7%) was common among female. Waghmode et al<sup>11</sup> reported similar findings of nylon material being the commonest (65%) in their study. Our findings are also dissimilar to reported by Vijayakumari et al<sup>10</sup> and Mødi et al<sup>19</sup>. However, Shrivastava et al<sup>7</sup> (2018) reported nylon rope in 15.7% cases. Cotton Dopatta in female was commonest ligature material that is consistent with previous studies<sup>16,17</sup>. Tongue protrusion (81%), bluish discoloration (79%), petechiae (71%) and salivary stains (37%) were common noted postmortem findings. The findings are similar to previous studies<sup>11,17-19</sup>. Shaikh et al<sup>13</sup> reported tongue protrusion in only 38.37% cases. The present study noted nylon rope as most common ligature in male and cotton dopatta in female while tongue protrusion, bluish discoloration, petechiae and salivary stains were



prominent postmortem findings.

### CONCLUSION:

In the present study of hanging cases, 83% were male and 17% were female. Majority of cases belonged to fourth decade of life. The complete and incomplete hanging was noted in 82% and 18% of cases respectively. Nylon rope was most common ligature in male and cotton dopatta in female. Tongue protrusion (81%), bluish discoloration (79%), petechiae (71%) and salivary stains (37%) were common noted postmortem findings.

### REFERENCES:

1. Reddy KSN. Mechanical Asphyxia: The Essentials of Forensic Medicine and Toxicology 34<sup>th</sup> edition 2017: 315.
2. Modi JP. A Textbook of Medical Jurisprudence and Toxicology 25<sup>th</sup> edition 2017:493.
3. World Health Organization. The Global Burden of Disease: 2004 update. Geneva: WHO; 2008.
4. Mohanty S, Sagu H, Mohanty MK, Patnaik M. Suicide in India: A four year retrospective study. *J Forensic Leg Med.* 2007; 14(2):185-9.
5. Gunnell D, Benne O, Hawton K, Simkin S, Kapur N. The epidemiology and prevention of suicide by hanging: a systematic review. *Int'l J Epidemiol.* 2005; 34(2):433-442.
6. Reddy KSN. The Essentials of Forensic Medicine and Toxicology. Published by K Sugunadevi 34<sup>th</sup> Edition 2009: 317.
7. Shrivastava M, Thakur PS, Pateria D, Singh BK, Soni SK. Autopsy based one year prospective study of death due to hanging. *Indian J Forensic Community Med.* 2018; 5(4):240-4.
8. Bhosle SH. Violent asphyxial death due to hanging: a prospective study. *J Forensic Med Sci Law.* 2014; 23(1):1-3.
9. Bharath GK. Profile and Pattern of Hanging Cases at a Tertiary Care Hospital, Khammam; Telangana. *Indian Acad Forensic Med.* 2016; 38(1): 67-71.
10. Vijayakumari N. Suicidal Hanging: A Prospective Study. *J Indian Acad Forensic Med.* 2011; 33(4):353-5.
11. Waghmode AH. Pattern of hanging cases brought for autopsy at a tertiary care centre in Central India. *Ind J Forensic Comm Med.* 2018; 5(3):190-2.
12. Azmak D. Asphyxial deaths: A Retrospective study and review of the literature. *Am J Forensic Med Pathol.* 2006; 27(2):13444.
13. Shaikh MMM, Chotaliya HJ, Modi AD, Parmar AP, Kalele SD. A study of gross postmortem findings in cases of Hanging and Ligature Strangulation. *J Indian Acad Forensic Med.* 2013; 35(1):63-65.
14. Sarangi MP. Ligature marks In Forensic Pathologist's perspective. *J Forensic Med Toxicol.* 1998; 15(1):99-102.
15. Nikolic S, Micic J, Atanasijevic T, Djokic V, Djonic D. Analysis of neck injuries in hanging. *Am J Forensic Med Pathol.* 2003; 24(1):179-182.
16. Ahmad M, Hossain MZ. Hanging as a method of suicide: retrospective analysis of postmortem cases. *JAFMC Bangladesh.* 2010;6(2):37-39.
17. Sharma BR, Harish D, Anup Sharma, Swati Sharma, Harshabad Singh. Injuries to neck structures in deaths due to constriction of neck, with a special reference to hanging. *J Forensic Leg Med.* 2008; 15:298-305.
18. Ashok Kumar Samanta, Soumya Rajan Nayak. Newer trends in hanging death. *J Indian Acad Forensic Med.* 2012;34(1):37-39.
19. Modi JP. A Textbook of Medical Jurisprudence and Toxicology 24<sup>th</sup> Edition. Nagpur, Butterworths Wadhwa. 2012:445-51.