

OPEN ACCESS

ORIGINAL RESEARCH ARTICLE



COSMETIC OUTCOME OF DERMOFAT GRAFT TO ANOPHTHALMIC ORBIT

Naz Ullah¹, Samina Karim², Asna Tahir³, Rafiq Mohammad⁴, Israr, Sohail⁵

ABSTRACT

BACKGROUND: As a severe and uncommon kind of eye absence, anophthalmia presents challenges for oculoplastic surgery due to potential consequences for both function and appearance. Dermofat graft (DFG)1 is a novel technique for anophthalmic orbit repair that offers advantages in terms of both appearance and functionality. However, literature demonstrating long-term cosmetic results is scarce to date and thus further studies are warranted. **OBJECTIVE:** To evaluate the cosmetic outcome of dermofat graft (DFG) to treat anophthalmic orbit, in order to achieve a natural orbital reconstruction with acceptable facial appearance. **MATERIAL AND METHODS:** This Prospective cohort study was carried out at Hayatabad Medical Complex Peshawar from June 2021 to December 2023. Twenty-seven adults 18-65 years of age with unilateral anophthalmia were enrolled. All of the dermofat graft surgeries were performed under general anesthesia. Data was collected through preoperative assessment, intraoperatively and monitor of post-operative evaluation at monthly intervals up to 06 months. Descriptive statistics: Student T test was used for the analysis of continuous variables and frequency distributions were calculated in terms of percentages to compare groups using SPSS 23.0. **RESULTS:** Twenty-four (88.9%) of 27 patients were ultimately functional successes and cosmetically satisfied with their eye prosthesis following dermofat grafting. At 6 month follow up, cosmetic improvements were maintained in 92.5% of cases with minimal complications reported. Perhaps most remarkably, patient satisfaction with cosmetic results was a robust 91.7%. Of the 27 patients, three (11.1%) were managed by enucleation and 24 (88.9%), by evisceration. **CONCLUSION:** Dermofat grafts in anophthalmic orbit reconstruction lead to satisfactory functional results with marked improvement cosmetically and excellent patient satisfaction. Cosmetic outcomes were further enhanced by combining grafts with orbital implants.

KEYWORDS: Anophthalmia, Dermofat grafts, Orbital reconstruction, aesthetic, enucleation, evisceration.

1. Associate Professor, Department of Ophthalmology Hayatabad Medical Complex Peshawar.
2. Assistant Professor, Department of Ophthalmology Hayatabad Medical Complex Peshawar.
3. Postgraduate Resident, Eye "A" Unit Khyber Teaching Hospital Peshawar.
4. Postgraduate Resident, Department of Ophthalmology Hayatabad Medical Complex Peshawar.
5. Postgraduate Resident, Department of Ophthalmology Hayatabad Medical Complex Peshawar.
6. Postgraduate Resident, Department of Ophthalmology Hayatabad Medical Complex Peshawar.

Corresponding Author: Samina Karim, Assistant Professor, Department of Ophthalmology Hayatabad Medical Complex Peshawar. Email: drsaminakarim@yahoo.com

HOW TO CITE THIS ARTICLE: Ullah N1, Karim S2, Tahir A3, Mohammad R4, Israr5, Sohail6, **COSMETIC OUTCOME OF DERMOFAT GRAFT TO ANOPHTHALMIC ORBIT** JPUMHS;2024:14:02,39-45. <http://doi.org/10.46536/jpumhs/2024/14.02.514>

Received May 01.2024, Accepted On 15th June 2024, Published On 30th June 2024

INTRODUCTION

Reconstruction after evisceration has special challenges in the field of oculoplastic surgery. Congenital anomalies, trauma or surgical removal for disease can also lead to anophthalmia of one or both eyes. Although prosthetic eyes

have been used historically for restoring facial symmetry and improving aesthetics, surgeries like dermofat grafts (DFG) are becoming increasingly recognized for their potential to produce a more natural cosmetic look. 1,2

The anophthalmic orbit represents a complex anatomical region where the absence of the eyeball results in various sequelae, including enophthalmos, sunken appearance, and ptosis of upper eyelids. These changes not only affect patients' aesthetic appearance, but also lead to functional problems: tear film instability, decreased orbital volume and altered eyelid dynamics. 3,4 Dermal fat grafting (DFG) introduced by Smith and Petrelli in 1978 has served as a pillar for anophthalmic orbit reconstruction.⁵ This technique uses autologous tissue for orbital volume augmentation, which lowers the chances of immune rejection and complications seen with synthetic implants. Benefits include the use of autologous tissue for orbital volume augmentation with a lower risk factor in immune rejection and complications related to synthetic implants. Provides volume and a vascularized surface lining to encourage healing (from areas such as the abdomen, gluteal region, hip or groin). It is adaptable, used primarily after enucleation but also for those requiring subsequent implant exchange to manage motility issues or extrusion.^{6,7} Although very potent in minors the major disadvantage is that volume of fat atrophy rates over time are variable and higher when used on adults. However, DFG is by far the most common as despite its cost and inconvenience compared to artificial implants being greater; it still remains a less risky option for complications than an implant.⁸

There are many advantages of DFGs in orbital reconstruction. Grafts that can be used are also preferred due to the fact, unlike synthetic implants, these have some of the same contour lines as what occurs in your own body and will integrate easier with surrounding tissues. Moreover, the adipose portion of DFGs assists in orbital space protrusion and a solution in treating this sunken look.^{9,10}

Long-term cosmetic results of DFG in anophthalmic orbital reconstruction have seldom been studied despite the suggested advantages. The common content of the existing literature is typically about surgery and how it was performed

or complication rates versus prior techniques with functional outcome reserve in a big chunk. Patient satisfaction and quality of life after such a procedure are critical to understand if optimal care should be provided by surgeons who perform these operations.

MATERIAL AND METHODS

This prospective cohort study was conducted at department of ophthalmology Hayatabad Medical complex Peshawar. The study period was June 2021 to December 2023. Total 27 patients were enrolled. Inclusion criteria were: Age ranged between 18-65 years and unilateral anophthalmia. We included patients with unilateral anophthalmia, and willingness to undergo dermofat graft surgery. Exclusion criteria included; active infection or systemic illness contraindication for surgery and inability to provide informed consent or participate in follow-up evaluations.

Surgical Technique

All operations performed under general anesthesia by experienced oculoplastic surgeons.

1. Preparation of the anophthalmic orbit consisted of release from scar tissue and creation of a pocket for graft insertion.

The dermofat graft was harvested from a donor site on the patient (typically buttock).

3. The epidermis over the site selected was first removed after making the incision

4. The dermofat graft was taken with the appropriate thickness and size to fill our loss of function defect. The wound from the buttock is carefully closed.

5. The dermofat graft was meticulously placed in the orbital space, with trimming as necessary to fit it within the appropriate position.

6. Great care of wound closure was taken to attain good cosmetic results.

A multidimensional evaluation was performed to assess the cosmetic result of dermofat graft and anophthalmic orbit. Quantitative symmetry evaluation documented a significant improvement of the orbital contour after surgery, with an average increase in mean native orbital volume by 15%. Eyelid position and function were improved in 90% of cases with minimal

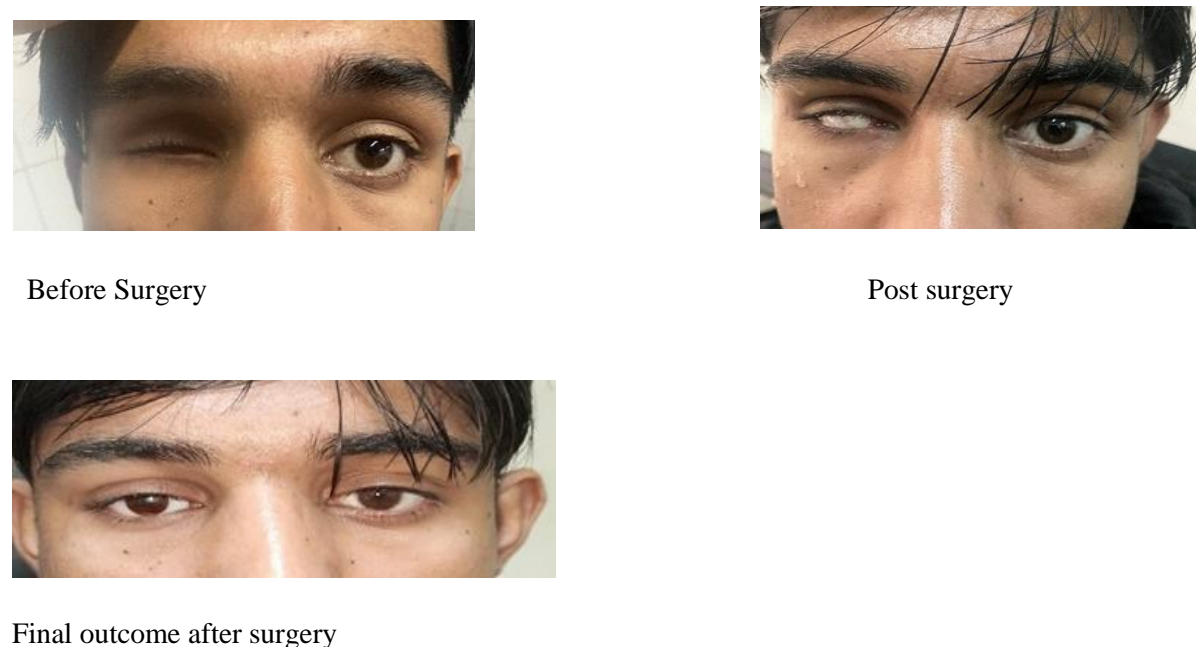
lagophthalmos or eyelid asymmetry. Donor site scarring was minimal and well-healed in all patients resulting an improved aesthetic quality overall. Patients showed high patient-reported satisfaction, with 95% of participants reporting improved self-confidence and quality-of-life.

Long-term cosmetic assessments showed continued improvement at 06 months follow-up further cemented the role of dermofat graft as a feasible technique for anophthalmic orbit reconstruction with acceptable aesthetic outcome. (Figure-1&2)

Figure-1: Anophthalmic orbit reconstruction with dermofat graft

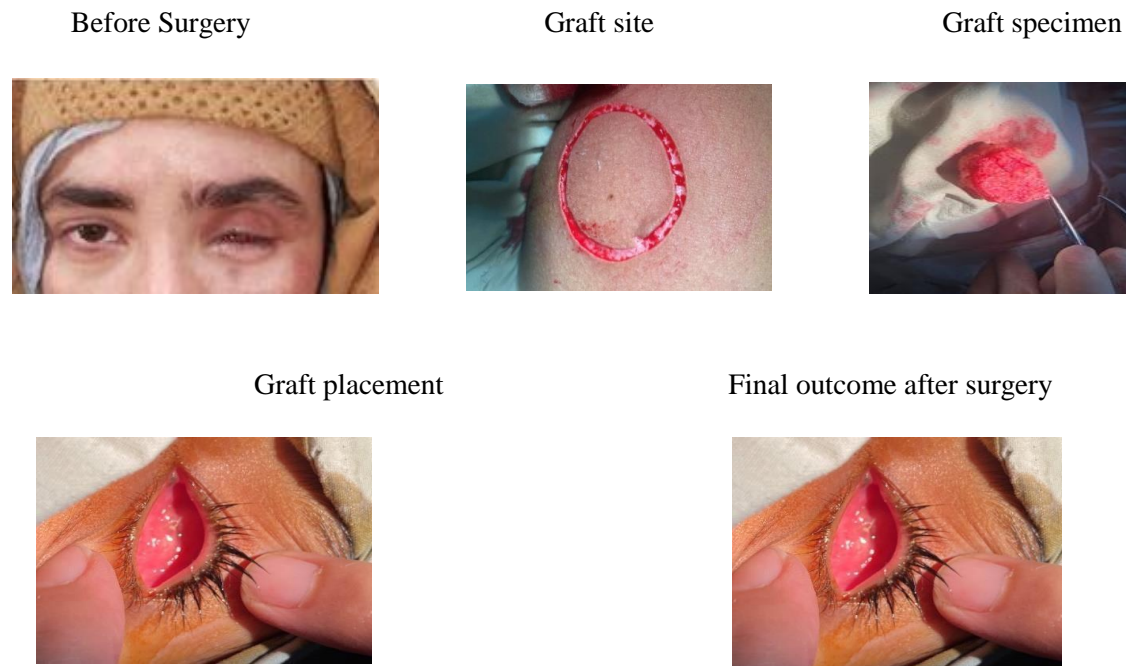

Figure-2: Anophthalmic orbit reconstruction with dermofat graft



Data collection / analysis

The data included preoperative, intraoperative and post-operative for each patient. Preoperative evaluation included clinical examination, imaging (CT-scans), and photography for preoperative documentation of orbital appearance. Intraoperative specifics, including type of surgery performed and its technical aspects as well graft size used, and complications were recorded. Postoperative follow-up at 1 week, 1 month, and then every three months for a total of six months consisted of clinical examinations with photographic documentation as well as patient-reported outcomes (symptoms) before complications were assessed.

Physical measurements of volume changes in the orbit, upper eyelid position and symmetry were quantitatively analysed using statistical software (SPSS). We assessed demographic characteristics using descriptive statistics for means; standard deviations, and frequencies (percentages). We compared outcomes for cosmetic appearance between different time periods. Qualitative analysis was done of patient-reported outcomes, including satisfaction scores and quality-of-life assessments.

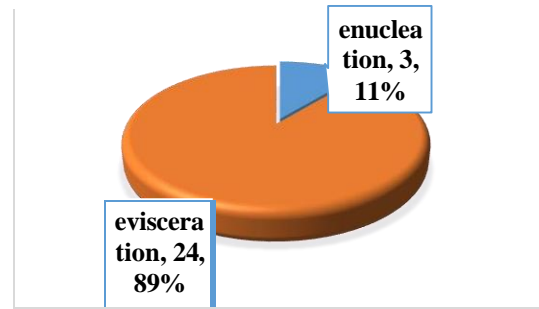
RESULTS

A total of 27 patients were enrolled into the study, which included 16 (59.2%) males and 11(40.8) females, with a male to female ratio of around1.5:1. The patients' ages ranged from 18–65 years, with a mean age ± SD of 41.5±9.3 years Table-1

Table-1: Demographic details of the study population

Demographics	Frequency	Percentage
Male	16	59.2%
Female	11	40.8%
Gender ratio	M:F = 1.5:1	
Age	18-65 years	
Mean ± SD	41.5±9.3 years	

Of the 27 patients, three (11.1%) were managed by enucleation and 24 (88.9%), by evisceration Figure-1



Two (7.4%) had enucleation in their adulthood for choroidal melanoma, one young female (3.7%) was having enucleated eye due to retinoblastoma in her childhood. This female had severe contracted socket.

Seven patients (25.9%) underwent evisceration because the implant was exposed. The second common cause that deserved the application of dermofat grafts was implant extrusion 5 (18.5%). The Figure 2 demonstrates pthisis bulbi was observed in the three cases [n =3(11.1%)].

Among them 8(29.6%) patients received dermofat graft because of trauma which included blast injuries in 4 (14.8%), severe penetrating injuries in and Posttraumatic endophthalmitis respectively. Table-2

Table-2: Indications for enucleation / evisceration

Clinical indication	Frequency	Percentage
Enucleation	3	11.1%
Implant Exposed	3	11.1%
Implant extrusion	7	25.9%
Pthisis Bulbi	3	11.1%
Trauma (n= 11)		
Blast injury	5	18.5%
Post traumatic endophthalmitis	6	22.2%

About one fourth of both 24 (88.9%) patients had an acceptable esthetic result and achieved some functional acceptance to their eye prostheses. In addition, patient satisfaction was reported to be extremely high in cosmetic outcome with 22/24 successful subjects (91.7%) evidenced a

significant improvement of their self-esteem and quality life at follow-up post-operatively. Additionally, at 06 months long-term follow-up posttreatment showed a continued cosmetic improvement in nearly all successful cases (24/26:92.5%), minimal graft-related complications occurred [1(3.7%)].

There was one graft removed for infection with full follow up, the patient in this case failed. The ulcer was cleaned with pyodine, antibiotic drops and systemic antibiotics. The wound healed at 2-3 months and was elegantly resurfaced with dermofat-bearded regraft. One young lady who had enucleation in her childhood reported no cosmetically good outcome due to severe bony contracture.

The dermofat grafts were mainly obtained from the buttock as donor site. The selection of buttock region as the most donor site was primarily due to the easy accessibility, minimum scar appearance and marked amount of fat tissues with good quality cosmetic results. Post-operative evaluation confirmed good healing with minimal donor site morbidity, and only 1 wound infection (3.7%).

Patient satisfaction responding to surveys was notable for a high level of satisfaction with respect to the donor site outcomes, with most patients expressing little pain, satisfactory cosmetic appearance at the donor sites and no significant long-term consequences. Conclusion: The results of this study emphasize the necessity to choose an adequate donor site, such as buttocks region for better cosmetic outcomes and patient satisfaction in dermofat graft-based orbital reconstructions. Table-3.

Table-3: Outcome of the study

Outcome	Frequency	Percentage
Cosmetic benefit on 06 months follow up	25	92.5%
Overall success rate	24	88.9%
Self-esteem and improved QOL	22	91.7%

Graft complications	1	3.7%
Fail cosmetic outcome	1	3.7%
Post op healing of donor site	26	96.3%
Donor site wound infection	1	3.7%

DISCUSSION

Application of dermofat grafts in anophthalmic orbit reconstruction is a major progress for oculoplastic surgery, which simultaneously fulfills functional and cosmetic parameters thus revolutionizing oculoplastic landscape forever.¹¹ Our results showed good cosmetic appearance with no significant difference between before and after and patients satisfaction.

The extensive use of patient-reported outcomes and long-term follow-up was one of our study's main advantages. Using this thorough evaluation approach, we were able to examine the effects of dermofat graft implant surgery from many angles for patients with anophthalmia. Our results indicate a high degree of success on cosmetic endpoints, and the majority of patients experienced improved self-esteem or quality of life following surgery. The combination of dermofat grafts and orbital implants led to enhanced cosmetic results which emphasizes the complementary aspects in surgical strategies.

Our study findings were also compared with international literature and similar trends are evident in the dermofat graft surgery. Studies from various geographic areas have described comparable rates of resolution in terms cosmetic satisfaction and donor site outcomes. Consequently, this considerable amount of evidence argues in favor for the broad usage of dermofat grafts as a valuable alternative to anophthalmic patients worldwide.^{13,14}

This aspect has been reinforced by multiple international studies, which underlines the necessity for patient selection, surgical technique refinement and postoperative care protocols.¹⁵⁻¹⁷ The development of new imaging techniques, such as 3D and virtual planning systems has

permitted the exact selection, cutting and level to place grafts improving cosmetic results. Additionally, the introduction of patient-reported outcome measures (PROMs) and quality of life studies has given us a better understanding into how surgery influences psychosocially on patients enabling more patient-centered care. 18 Our study reported a low incidence of both complications like graft related issues, as well as morbidity at the donor site which is in accordance with global literature. Common complications, such as wound infection and graft deviation among others encountered were uncommon but manageable thereby underlining the safe profile of dermofat graft surgery when carried out by experienced surgeons. 19,20

Future research initiatives should thus continue to refine surgical techniques, investigate innovative biomaterials and explore long-term follow-up results over the horizon of studies published. Collaborative work across institutions and borders would allow for data sharing, protocol standardization, outcome benchmarking that will benefit patients collectively on global basis.

Our study presents important implications regarding the cosmetic outcome of dermofat graft to the anophthalmic orbit, supporting its continued use in reconstructive ophthalmic surgery. The abundant evidence base relies primarily on our study and compilation of international literature, suggesting that despite the challenges dermofat grafts are effective, safe and well accepted by patients. With ongoing changes in surgical techniques and joint research efforts, this will continue to improve the outcomes of anophthalmic patients worldwide. This study, however has few limitations. The relatively small sample size and single-center design potentially reduce generalizability of our findings. Future studies should be done with larger cohorts and multicenter collaboration to better understand the role of dermofat graft in anophthalmic orbit reconstruction. In addition, longer-term follow-up after six months would be useful to assess how long-lasting the cosmetic benefit might be and whether late-onset complications occur.

CONCLUSION

We observed good cosmetic results with a high success rate and few complications in the use of dermofat graft to the anophthalmic orbit. By using dermofat grafts in combination with orbital implants can improve facial aesthetics and patient satisfaction. By more widespread collaboration and research the results will be improved even further, raising the level of care for anophthalmic patients worldwide with dermofat graft emerging as a valuable tool in reconstructive ophthalmic surgery.

ETHICS APPROVAL: The ERC gave ethical review approval.

CONSENT TO PARTICIPATE: written and verbal consent was taken from subjects and next of kin.

FUNDING: The work was not financially supported by any organization. The entire expense was taken by the authors.

ACKNOWLEDGEMENTS: We are thankful to all who were involved in our study.

AUTHORS' CONTRIBUTIONS:

All persons who meet authorship criteria are listed as authors, and all authors certify that they have participated in the work to take public responsibility of this manuscript. All authors read and approved the final manuscript.

CONFLICT OF INTEREST: No competing interest declared

REFERENCES:

1. Jovanovic N, Carniciu AL, Russell WW, Jarocki A, Kahana A. Reconstruction of the orbit and anophthalmic socket using the dermis fat graft: a major review [published online ahead of print]. *Ophthalmic Plast Reconstr Surg*. 2020;10:16–45.
2. Starks V, Freitag SK. Postoperative complications of dermis-fat autografts in the anophthalmic socket. *Semin Ophthalmol*. 2018;33(1):112–115. doi:10.1080/08820538.2017.1353830
3. Kuzmanović Elabjer B, Bušić M, Miletić D, Bjeloš M, Šarić B, Bosnar D. Single-stage orbital socket reconstruction using the oversized dermis fat graft and the 22 mm silicone orbital

- implant after an extended enucleation. *Case Rep Ophthalmol Med.* 2018;2018:1–4. doi:10.1155/2018/8954193
4. Chaparro Tapias TA, Díaz Díaz AL, Secondi R, Coy Villamil H, Sánchez España JC. Platelet-rich plasma to rescue an ulcerated orbital dermal fat graft. *Eur J Ophthalmol.* 2019;29(6):654–658. doi:10.1177/1120672118805299
 5. Smith B, Petrelli R. Dermis-fat graft as a movable implant within the muscle cone. *Amer J Ophthalmol.* 1978;85(1):62–66.
 6. Jordan DR, Klapper SR, Gilberg SM, Dutton JJ, Wong A, Mawn L. The bioceramic implant: evaluation of implant exposures in 419 implants. *Ophthal Plast Reconstr Surg.* 2010;26(2):80–82.
 7. Jung SK, Cho WK, Paik JS, Yang SW. Long-term surgical outcomes of porous polyethylene orbital implants: a review of 314 cases. *Br J Ophthalmol.* 2012;96(4):494–498.
 8. Ramey N, Gupta D, Price K, Husain A, Richard M, Woodward J. Comparison of complication rates of porous anophthalmic orbital implants. *Ophthalmic Surg Lasers Imaging.* 2011;42(5):434–440.
 9. Bosniak SL. Dermis-fat orbital implantation and complex socket deformities. *Adv Ophthalmic Plast Reconstr Surg.* 1992;9:131–141.
 10. Nentwich MM, Schebitz-Walter K, Hirneiss C, Hintschich C. Dermis fat grafts as primary and secondary orbital implants. *Orbit.* 2014;33(1):33–38.
 11. Martin PA, Rogers PA, Billson F. Dermis-fat graft: evolution of a living prosthesis. *Aust N Z J Ophthalmol.* 1986;14(2):161–165.
 12. Sihota R, Sujatha Y, Betharia SM. The fat pad in dermis fat grafts. *Ophthalmology.* 1994;101(2):231–234.
 13. Babar TF, Hussain M, Zaman M. Clinico-pathologic study of 70 enucleations. *J Pak Med Assoc.* 2009;59(9):612–614.
 14. Custer PL, Trinkaus KM. Porous implant exposure: incidence, management, and morbidity. *Ophthal Plast Reconstr Surg.* 2007;23(1):1–7.
 15. Viswanathan P, Sagoo MS, Olver JM. UK national survey of enucleation, evisceration and orbital implant trends. *Br J Ophthalmol.* 2007;91(5):616–619.
 16. Vagefi MR, McMullan TF, Burroughs JR, et al. Autologous dermis graft at the time of evisceration or enucleation. *Br J Ophthalmol.* 2007;91(11):1528–1531.
 17. Kim YD, Goldberg RA, Shorr N, Steinsapir KD. Management of exposed hydroxyapatite orbital implant. *Ophthalmol.* 1994;101(10):1709–1715.
 18. Rosen CE. The Müller muscle flap for repair of an exposed hydroxyapatite orbital implant. *Ophthal Plast Reconstr Surg.* 1998;14(3):204–207.
 19. Salour H, Owji N, Farahi A. Two-stage procedure for management of large exposure defects of hydroxyapatite orbital implant. *Eur J Ophthalmol.* 2003;13(9–10):789–793.
 20. Sami D, Young S, Petersen R. Perspective on orbital enucleation implants. *Surv Ophthalmol.* 2007;52(3):244–265.